

Behavioral Variant of Frontotemporal Dementia and Homicide in a Historical Case

Stefano Zago, PhD, Cristina Scarpazza, PhD, Teresa Difonzo, PsyD, Andrea Arighi, MD, Dounia Hajhajate, PsyD, Yvan Torrente, MD, PhD, and Giuseppe Sartori, PhD

Criminal behavior is a clinical feature of the behavioral variant of frontotemporal dementia (bvFTD), ranging from socially inappropriate behavior and minor offenses (such as shoplifting, driving-related violations, housebreaking, trespassing) to the more extreme acts of sex crimes and violence. To our knowledge, no homicide case involving bvFTD is well illustrated in the scientific literature, and only a few anecdotal annotations are available about bvFTD and homicide. This is surprising considering the inclination of individuals with bvFTD to lack impulse control, to manifest disinhibition, to display diminished emotional awareness and loss of empathy, and to show behavior indicative of disordered moral reasoning. Here, we describe the 19th-century homicide case of Benjamin Reynaud, a man whose clinical characteristics suggest the bvFTD diagnosis. Reynaud's case may represent a rare instance of homicide committed by an individual with bvFTD and provide a basis for some reflections regarding the relationship between homicidal behavior and bvFTD.

J Am Acad Psychiatry Law 49(2) online, 2021. DOI:10.29158/JAAPL.200081-20

Key words: behavioral variant frontotemporal dementia; criminal behavior; homicide; murder

A significant inclination to crime has been described in individuals with a diagnosis of a behavioral variant of frontotemporal dementia (bvFTD), the most common clinical phenotype of frontotemporal lobe degeneration.^{1,2} Persons with bvFTD often demonstrate a slow decline in social interpersonal conduct and regulation of personal behavior along with a lack

of insight and emotional blunting.^{3,4} Execution-related cognitive deficits in inhibitory control, flexibility, abstract reasoning, decision-making, and goal-oriented behavior are often evident in individuals with bvFTD.⁴ Structural and functional imaging studies have shown that bvFTD involves a large network of structures including the dorsolateral prefrontal and orbitofrontal cortex, anterior insula, anterior cingulate and adjacent medial prefrontal cortices, amygdala, striatum, and thalamus.² To date, a diagnosis of bvFTD is based primarily on clinical diagnostic criteria, while brain-imaging and genetic data are considered supportive criteria.⁴ In 2011, the International Behavioral Variant of Frontotemporal Dementia Criteria Consortium established the criteria for diagnosis of bvFTD.⁴ Currently, there are no known treatments to stop or reverse the progression of bvFTD. Some medications have been useful in regulating and controlling behavior, including antidepressant and antipsychotic medications and even intranasal oxytocin.⁵⁻⁷

In the last decade, the literature indicates that transgression of social norms and criminal behavior

Published online March 17, 2021.

Dr. Zago and Dr. Difonzo are Clinical Neuropsychologists, Neurology Unit, Fondazione IRCCS Cà Granda Ospedale Maggiore Policlinico, Milan, Italy. Dr. Scarpazza is Assistant Professor and Dr. Sartori is Professor, Department of General Psychology, University of Padua, Padua, Italy. Dr. Arighi is a neurologist, Neurodegenerative Disease Unit, Fondazione IRCCS Cà Granda Ospedale Maggiore Policlinico, Milan, Italy, and Centro Dino Ferrari, University of Milan, Milan, Italy. Dr. Hajhajate is Clinical Research Assistant, Sorbonne Université, Paris, France. Dr. Torrente is Associate Professor, Department of Pathophysiology and Transplantation, University of Milan, Milan, Italy. Address correspondence to: Stefano Zago, PhD. E-mail: stefano.zago@unimi.it.

The present study was carried out within the scope of the research program 'Dipartimenti di Eccellenza' (art.1, commi 314-337 legge 232/2016), which was supported by a grant from MIUR to the Department of General Psychology, University of Padua.

Disclosures of financial or other potential conflicts of interest: None.

are more frequent in individuals with a diagnosis of bvFTD compared with other forms of dementia (e.g., Alzheimer's disease, vascular dementia, Lewy body disease). Among them are the extensive systematic studies in Europe by Diehl-Schmid *et al.*,⁸ in North America by Liljegen *et al.*,⁹ and in Asia by Shinagawa *et al.*¹⁰ These data are supported by less systematic investigations that have reported a high incidence of criminal violations among such individuals.^{6,8,11-16} It is estimated that 37 to 57 percent of those with a diagnosis of bvFTD have committed a crime or acted inappropriately.^{8-10,13,15} An inclination to crime can sometimes be the early sign of bvFTD^{9,17}; in addition, individuals with bvFTD interact with the police more frequently during the course of their disease compared to those with Alzheimer disease.¹⁸

The crimes that are most likely to be observed in individuals with bvFTD range from poor awareness of and adherence to social boundaries (e.g., theft, traffic violations, trespassing) to unlawful acts (e.g., indecent behavior, willful damage to property, shoplifting, house-breaking, physical assault, sexual harassment, pedophilia). To our knowledge, no individuals with bvFTD who have attempted or committed homicide have been described within the scientific literature, either in group studies or as a single case. This finding was unexpected because the behavioral disinhibition, the poor physical impulse control, and the progressive decline in judgment and empathy are already known in individuals with bvFTD. In Liljegen *et al.*,⁹ more than 6.4 percent of subjects with bvFTD exhibited physical or verbal violence, and in four percent of them violence was one of the first symptoms of the disease.

Reported Cases

Currently, only a few anecdotal annotations are available about frontotemporal lobe degeneration and homicide. In a retrospective medical record review study from 36 departments for geriatric psychiatry in psychiatric state hospitals in Germany, Ibach *et al.*¹⁹ found 33 patients with a clinical diagnosis of frontotemporal lobe degeneration, of whom one had also committed a homicide. The authors noted that: “. . . the presence of a patient who committed a homicide emphasizes that forensic psychiatry could be involved in frontotemporal lobe

degeneration diagnosis, prognosis, and associated legal questions” (Ref. 19, p 261).

In another study, Hatem *et al.*²⁰ reported three patients with dementia each of whom had killed their wives. For one of them, a 90-year-old man, the diagnosis of frontotemporal dementia was made on the basis of: a computed tomography scan showing diffuse cortical and subcortical atrophy predominantly in the frontal regions; a neuropsychological exam highlighting dysexecutive deficits; and the presence of psychiatric symptoms such as excessive jealousy, delusions of persecution, and hallucinations.

In 2013, the case of J.G., a 41-year-old American man, was reported because he fatally shot his 64-year-old mother and then took his own life. A diagnosis of Pick's disease (i.e., a subtype variant of frontotemporal lobe degeneration that greatly affects behavioral control) was invoked to explain J.G.'s personality changes. The man had a significant family history for Pick's disease given that his father, brother, and several other family members had died of this neurodegenerative disorder.²¹

In 2014, A.S., a 40-year-old American man affected by both bvFTD and amyotrophic lateral sclerosis (a comorbidity that is well known within the literature^{22,23}) killed his wife and sister-in-law.²⁴ Jurors found him not legally responsible for the killings due to mental illness.²⁴

In 2015, Adonis Sfera, a psychiatrist at Patton State Hospital in Orange County, California, described a patient with murderous intent in the context of the Alzform Networking for a Cure, a forum dedicated to the criminal actions of patients with frontotemporal lobe degeneration.²⁵ The patient was a 59-year-old woman who suddenly bought a gun and shot her neighbor in the shoulder. She was convicted of attempted murder, sent to prison, and then transferred to Patton State Hospital because of her mental symptoms. A positron-emission tomography scan revealed frontotemporal hypometabolism, and a diagnosis of bvFTD was made. Based on the diagnosis of probable bvFTD, a court permitted her release to a lower care setting.²⁵

In 2018, a murder trial in the United Kingdom attracted widespread media attention. M.G., an 84-year-old English woman, fatally stabbed her 85-year-old husband with a kitchen knife, once in the chest and twice in the back, without apparent reason.^{26,27}

Following medical and neuropsychological examinations, a diagnosis of bvFTD was made. The judge, recognizing the presence of the disease, sentenced M. G. to detention at a specialist hospital.^{26,27}

In addition to these cases of homicide or attempted murder, some authors have reported cases of fronto-temporal lobe degeneration in patients' homicidal threats or homicidal statements (such as "sniping people").^{28,29} Finally, we note the case discussed by Dunlop and Lemmen,³⁰ in which a bvFTD diagnosis was put forward in an unsuccessful appeal of a murder conviction and death sentence in Florida.

In the following section, we utilize a historical case to deal with such a modern but neglected topic. We describe a 19th-century homicide case in which clinical characteristics are suggestive of bvFTD. This case could represent a rare instance of homicide by an individual with possible bvFTD and provides grounds for contemplating the relationship between bvFTD and violent crime, such as homicide.

The Case of Benjamin Reynaud, 1861

In 1868, the French physician and criminologist, Prosper Pierre Constant Despine (1812–1892) published a report³¹ of a case of *folie morale produite par de graves modifications survenues dans le cerveau* [moral madness produced by serious changes in the brain] (Ref. 31, pp 598–603). The case report described Benjamin Reynaud, a 67-year-old man who previously worked in the magistracy as an employee, who was charged with murder for killing his own daughter and trying to murder her fiancé in their house on November 4, 1860. The case and trial were extensively described in a daily newspaper, *L'Indépendance Belge*, on March 26, 1861, and in the British magazine *The Spectator* on March 30, 1861. Short historical notes also appeared in an 1869 issue of *The Annals of Our Time*, a British daily journal of events from abroad, and in the March 25, 1944, section *To-day and Yesterday of The Solicitors' Journal*, a law journal edited in London. From these journalistic notes emerged a clear interest in the case, even if the abnormal behavioral aspects of Benjamin Reynaud are captured only in *L'Indépendance Belge*.

In 1875, the Austro-German psychiatrist and neuropathologist Richard Freiherr von Krafft-Ebing (1840–1902), who pioneered the systematic study of sexually inappropriate disorders, included the case of Benjamin Reynaud in his textbook *Judicial*

*Psychopathology*³² as an example of homicide due to a progressive impairment of moral sense because of a senile dementia.³² He described the case as follows (translation from German by the authors of this article):

In March 1861, the Court of Grenoble tried Mr. Reynaud, a 67-year-old man, charged with the murder of his own daughter. Reynaud's behavior had been impeccable until some years before; he was considered a model of morality, religiosity, and a good family man. However, gradually his behavior manifested a deep and inexplicable change. He had gone from being a prudish and respectable man to a debauched womanizer where one might look in vain for a trace of shame. Regarding the reasons of this change, no other hypothesis could be made except that of a senile involution of his brain, which can sometimes lead to a moral transformation of the individual. Reynaud's life in recent years was characterized by sexual excesses; he lived together with one woman but at the same time he carried on a sexual relationship with a young 26-year old woman. The letters he wrote to the latter were full of depravity; he made her obscene proposals; the passion and sexual desire his expressions were impregnated with are hard to be found even in a young man. Reynaud's exaggerated sexual instinct was confirmed by the testimonies of 20 other women with whom he usually had sexual relationships over recent years. The crime that led him to trial at the Assize court was to have killed his daughter, not out of moral outrage, out of jealousy. He fired a gunshot at the lover who was shot in the back as he tried to escape through a window and then killed his daughter with a dagger. When the lover ran to assist her, he found her in agony. While he prayed over her, the murderer indulged in contemplating his daughter's naked breasts, saying: "What a beautiful piece of woman she was! What a beautiful girl!" Reynaud allowed himself to be arrested with the greatest indifference, nor did he show later second thoughts or regret. He sat down in the dock with a self-satisfied attitude, while sniggering, and he, with total indifference, listened to his sentence that condemned him to life with hard labor (Ref. 32, pp 169–70).

As reported by the newspapers of the time and from the documentation obtained at the Court of Grenoble (see Fig. 1 for an example of the original document), we know that, earlier in his life, Benjamin Reynaud went to l'Île-Saint-Denis de la Réunion, where he became a magistrate's clerk dealing with duty and taxes, an important career position in the colony that allowed him to enjoy a substantial income. While there, Reynaud married and had five children.

His conduct had been impeccable, and he was described as a good and educated man, considered to be a moral and religious example and an excellent family man. No criminal record, mental disorders, neurologic disorders, alcohol abuse or other medical affliction appear in his past history. He retired in 1847, when he was 53 years old.

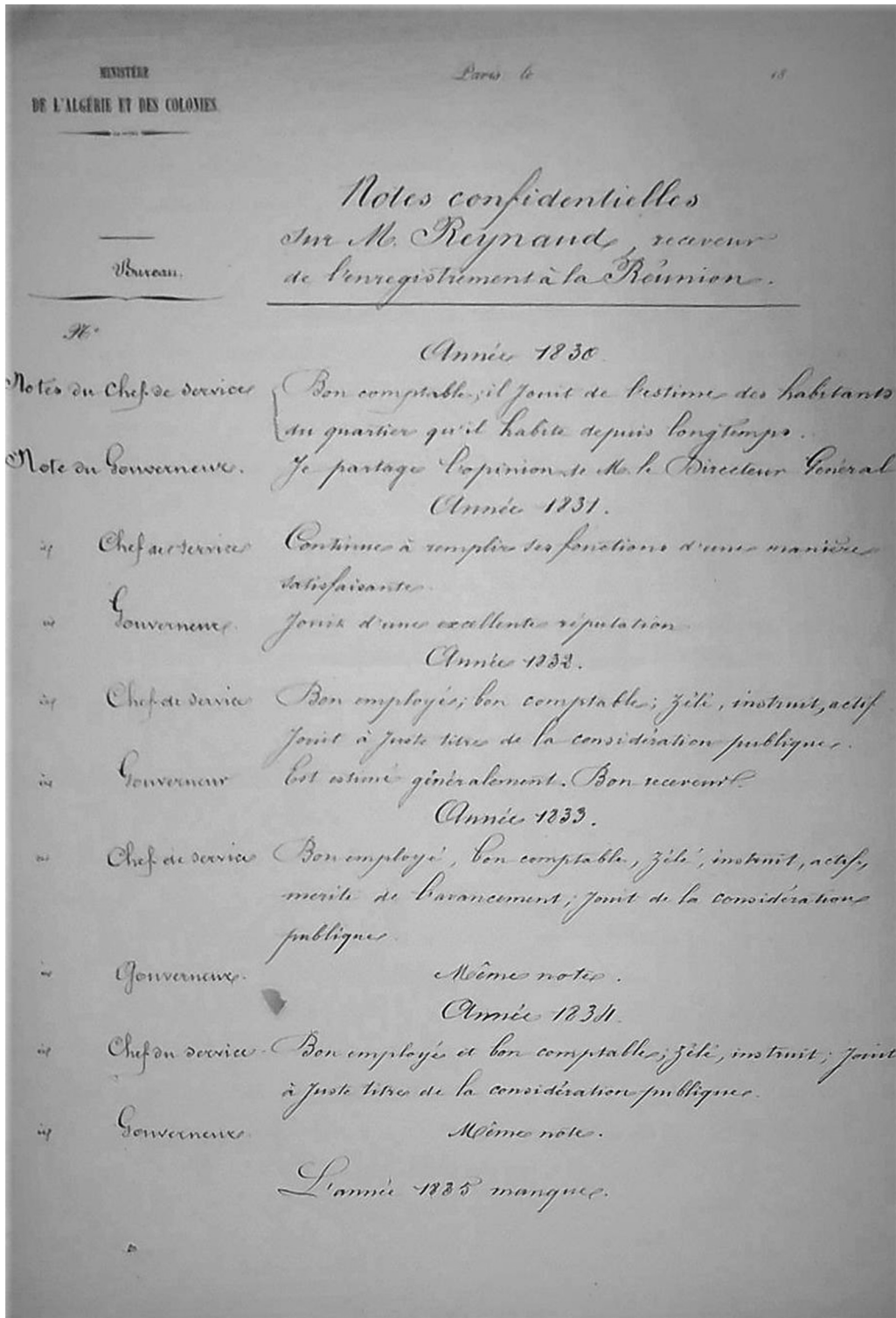


Figure 1. Confidential notes about Mr. Benjamin Reynaud conserved in Les Archives départementales de l'Isère (carton coté 4 U 367). (These documents are open to the public.)

On entering his sixties, Reynaud settled in a country house at Clary, near Grenoble. During this period, his manifest behavior gradually

underwent a profound and baffling change, including increasingly promiscuous sexual behavior. Reynaud's hypersexuality was also confirmed

by the approximately 20 mistresses with whom he had sexual relationships during recent years and who testified to his “erotic madness” during the trial.

His wife knew that he was being unfaithful, and she eventually left him to return to her married daughters in the colony of Saint Denis. One of the daughters, Madame Gardilanne, separated from her husband and went to live with her father in Clary. Reynaud started an incestuous relationship with the daughter; at the same time, he had brought a girl into his home and was also having a relationship with another young woman, Madame Baudrand, the wife of a notary. To the latter, Reynaud sent letters that were full of peculiarities and sexual references that, as von Krafft-Ebing points out: “. . . would have been barely tolerated even if written by a young boy” (Ref. 32, pp 169–70). Reynaud learned that his daughter was in a relationship with Mr. Lobinhes, a young man who was responsible for local stamp duties and had recently arrived in the area. Moved by pathological jealousy, Reynaud wanted to kill his daughter, her lover, and then himself. He had a dagger and two pocket pistols that were already loaded with a single shot by the clerk from the store where he bought them. On November 4, 1860, he surprised the couple while they were at home. The young man asked forgiveness and urged Reynaud not to commit such a horrific crime, which he would bitterly regret. Reynaud said, “I don’t forgive you: take a pen.” Lobinhes took a pen and he wrote under dictation: “I admit I’m an infamous instigator.” He put the pen down and declared that nothing would force him to write it. Reynaud then threatened to shoot. Lobinhes said, “Give me a moment. Let me say a prayer.” A moment of hesitation ensued after this appeal, and Lobinhes rushed to a window; as he was jumping out, Reynaud fired and wounded him. After that, he stabbed his daughter three times, sinking the dagger to its base, as evidenced by the autopsy examination, and leaving her dying on the floor. He then shot himself in the mouth but the bullet only took away a little portion of the upper jaw without causing serious injuries. Meanwhile, Lobinhes returned upstairs and, seeing that Madame Gardilanne was close to death, thought of nothing but to pray for her. Reynaud, despite being conscious and not seriously injured, did not shoot Lobinhes again. Furthermore, Lobinhes reported that when Reynaud saw his own

daughter dead, he exclaimed: “What a beautiful piece of woman she was! What a beautiful girl!” He was arrested and taken to Marseille prison.

On March 21, 1861, Reynaud appeared before the Assizes Court of the Isère in Grenoble. As reported by *L’Indépendance Belge*, during his arrest Reynaud showed total indifference and no remorse for his criminal act. During the trial, despite appearing concentrated on the discussion, he was attracted by the presence of a young woman sitting in front of him. The jury ruled that he was not moved by the purpose of safeguarding a particular form of honor or reputation, but rather by the concern of seeing the object of his incestuous love stolen. In listening to the sentence that, with extenuating circumstances, condemned him to hard labor for life, Reynaud appeared indifferent, sneering and satisfied with what he had done. In that French law forbids hard labor for individuals over 60 years old, he was sentenced to life in prison and not the death penalty. Unfortunately, it is not known whether Reynaud was assisted by an expert consultant, whether an insanity defense was proposed, or whether additional evidence besides age affected the ruling of the judges and jurors. Furthermore, there is no information about Reynaud’s period of detention or even his death.

Discussion

At the time of Despine’s report, the frontotemporal variant of dementia had not yet been defined. It was only in 1892 that the Czech neuropsychiatrist Arnold Pick (1851–1924) described a case with behavior and language disturbances associated with a predominantly left frontotemporal degeneration at postmortem examination. Pick regarded the patient as a person with a variant of senile dementia^{33,34} (see Ref. 35 for Pick’s major contributions to the study of behavioral neurology).

Although Despine described only a generic senile dementia in Reynaud’s case, he included the case in the section of organic rather than psychiatric diseases. In the 19th century, it was customary to consider murderous acts as caused by psychiatric disorders (e.g., melancholia with the delusion of persecution, psychopathy) or by neurological diseases (e.g., alcohol abuse, epilepsy). The sudden behavioral change and Reynaud’s disproportionate sexual attitude led Despine to hypothesize a degenerative brain disease. This hypothesis clearly indicates that Despine

conceptualized an organic, rather than functional, origin of the behavioral changes observed in Reynaud.

Today we can recognize in Reynaud's abnormal behavior some clear elements in favor of possible bvFTD. First, he had a major personality change (criterion I-A for bvFTD)⁴ characterized by socially inappropriate behavior, namely increased and inappropriate sexual activity (i.e., loss of decorum and behavioral disinhibition; criterion II-A for bvFTD). An early change in lifestyle in the previous two to three years is one of the primary criteria for the diagnosis of bvFTD,⁴ and sexually uninhibited behavior or hypersexuality is also a frequently reported symptom in bvFTD.³⁶ Secondly, although we cannot precisely establish the evolution of Reynaud's uninhibited disorder, it did not seem to diminish over time, and it is conceivable that it remained consistent over the years, leaving open the hypothesis of a clinical progression. Thus, Reynaud's case fulfilled all three A-level criteria of the International Behavioral Variant of Frontotemporal Dementia Criteria Consortium (e.g., inappropriate social behavior; loss of manners and decorum; and impulsiveness, rashness, or unhealthiness).⁴ Reynaud's case also presented additional aspects suggestive of bvFTD, such as the incapacity to recognize his abnormal sexual behavior and relationships, the absence of remorse for the criminal acts he committed, the emotional bluntness he manifested during the trial (criterion II-C for bvFTD), the inappropriate comments he made, and the difficulty in planning goal-directed behavior.

In our opinion, two points need to be discussed further to allow the reader to understand fully the Reynaud case. First, Reynaud's failed effort to kill Lobinhos can be interpreted as indicative of bad aim. Despite being undoubtedly true, it is necessary to keep in mind that his social behavior declined during the years that preceded the homicide, demonstrating a behavioral fracture between the man he was before (i.e., a model of morality, religiosity, and a good family man) and the man he was at the moment he committed the crime (i.e., a sexually depraved man). Indeed, the motive for the crime was pathological jealousy toward the daughter, a motive that should be considered within the constellation of bvFTD-related symptoms because his jealousy was not present earlier in his life, the years that we can now consider premorbid. Here, it is important to note that pathological jealousy is a known and well recognized symptom of

bvFTD.³⁶ Secondly, the homicide was premeditated because he wanted to kill the daughter, the daughter's lover, and himself. For this reason, he bought the dagger and the pistols. The fact that the crime was premeditated does not imply that it was well planned. In Reynaud's case, poor planning and organizing are evident. For instance, he did not plan what he was going to do with the couple, he failed to anticipate that the young man would try to escape, he did not arrange to kill the stronger victim first, and so on. Moreover, when the young man came back, Reynaud did not try to finish the job. All of the available evidence thus converges in supporting the hypothesis that Reynaud was experiencing bvFTD at the time he committed the crimes.

Alternative diagnoses appear less likely in Reynaud's case. For example, in late-onset schizophrenia-like psychosis,³⁷⁻³⁹ the most prevalent symptoms at the onset are paranoid and persecutory delusions, which are not present in Reynaud's history, where only delusions of jealousy are reported. A diagnosis of a late-onset bipolar illness^{40,41} seems unlikely in light of the absent sense of guilt and the inappropriateness of Reynaud's comments. The hypothesis of homicide due to a slowly developing cerebral tumor involving the prefrontal cortex⁴²⁻⁴⁴ is also unlikely. Over the course of six to seven years after the onset of behavioral symptoms, Reynaud did not exhibit neurological disorders usually associated with cerebral tumors (e.g., epilepsy attacks, contralateral functional motor deficits, language disorders in the case of a left-sided cerebral lesion, etc.).

Moving from the Reynaud case, we provide some preliminary and speculative explanation of why homicide is a rare occurrence in bvFTD. One possible explanation is that, due to the degenerative process of the prefrontal cortex, the task of committing a homicide may be too difficult for individuals with bvFTD because of their inability to use executive functions adaptively, especially with regard to regulating one's goal-directed behavior. Poor executive functioning leads individuals with bvFTD to act mainly on the basis of environmental factors. In provocative situations, environmental dependency behaviors can trigger an aggressive and impulsive response.⁴⁵ Impairment in executive functions limits the ability of individuals with bvFTD to commit premeditated murders, which, to be carried out successfully, require good planning abilities, the ability to anticipate possible

problems, and the ability to react appropriately to unexpected circumstances.

Executive functions are presumed to be mediated predominantly by the dorsolateral region of the prefrontal cortex.^{46,47} Some studies have suggested that goal-directed premeditated murders are committed by offenders who present an intact capacity to regulate executive control processes.^{48–51} This is consistent with some positron-emission tomography studies that identified no differences in prefrontal glucose metabolism of planned homicide offenders compared with normal control subjects.⁵² Recent evidence suggests that premeditated murderers exhibit largely intact functioning across neurocognitive domains,⁵¹ which is not the case in individuals with bvFTD.

Another explanation is that an impulsive murder could be unlikely for individuals with bvFTD because of their difficulty in experiencing a wide range of strong emotions, an aspect present since the early phase of the disorder, probably due to the bilateral involvement of the insulae and subcortical structures such as the caudate, putamen, and hippocampus.^{53,54} This is relevant because impulsive murder is linked, by definition, to a triggering of emotion (i.e., rage or fear). Despite this topic being extremely complicated, it is likely that the emotional blunting frequently observed in individuals with bvFTD might reduce the likelihood of impulsive aggression. We can speculate that the emotional component can differentiate impulsive murder from other impulsive crimes frequently committed by individuals with bvFTD, such as sexual assault or social rule violations (i.e., traffic violation, public urination).^{6,9} Indeed, these other crimes are triggered by physical urges (e.g., sexual arousal in the case of sexual assault, or need for urination in the case of public urination) or by the inability to modulate behavior in accordance with environmental factors (e.g., inability to modulate speed coming to a traffic light, or inability to inhibit the urges to take what is wanted, etc.). It is thus possible to speculate that blunted emotions can affect the ability of individuals with bvFTD to commit impulsive murders, while not affecting impulsive crimes of another type that are not linked with emotions but with general disinhibition. This reasoning might explain why impulsive homicides are indeed frequently observed in individuals with bvFTD.⁹

Yet another explanation of why homicides are under-reported in individuals with bvFTD is that

some offenders in bvFTD-related homicide cases may have been misdiagnosed with psychiatric disorders. More than one study points out the difficulty in distinguishing bvFTD from possible psychiatric illness because bvFTD can mimic a psychiatric clinical picture; moreover, psychiatric symptomatology can co-exist with frontotemporal lobe degeneration.^{55–59} Health care providers are not usually familiar with bvFTD, and they can misdiagnose it as bipolar disorder or late-onset schizophrenia. On this subject, Sfera *et al.*⁶⁰ argued that patients with bvFTD can be found in correctional institutions due to difficulty in distinguishing bvFTD symptoms from a psychiatric disorder. Despite both bvFTD and late-onset psychosis being potentially relevant for insanity evaluation, the fact that bvFTD cases might have been misdiagnosed as psychotic ones may explain why homicide is under-represented in bvFTD.

Finally, even if it is not known if an insanity evaluation was requested in Reynaud's case, insanity might be a relevant consideration for individuals with bvFTD today who commit homicide. The legal implications and suggestions for dealing with aspects of the behaviors induced by bvFTD have been widely discussed elsewhere.^{61,62} It is important to highlight that the literature does not suggest that the identification of bvFTD in a defendant charged with crimes could *per se* preclude criminal responsibility.⁶⁰ Whether or not a defendant diagnosed with bvFTD should be held responsible needs to be assessed cautiously on a case by case basis. This assessment should address how neurobiological deficits affect the individual's capacity to control behavior, to evaluate rationally what is wrong and to decide to act accordingly, to feel emotionally the moral wrongness of an action, to recognize if actions are illegal or immoral, to understand the consequences of one's own action, to evaluate correctly and respond appropriately to verbal feedback from others, etc. Although this evaluation will vary according to the legal standard of each jurisdiction, we strongly suggest that it follow the cognitive model of free will.⁶³ According to this model, free will is manifested in an individual who can envision different behavioral choices, select the most appropriate one, inhibit unwanted behaviors, understand whether the behavior is socially and morally approved, and understand nonverbal emotional feedback of others.

Conclusions

Individuals with bvFTD are often relatively young and socially active, and they can commit criminal acts without being able to modulate or govern their instinctive urges sufficiently. These individuals may be guilty of unlawful acts against public morals, good manners, etc., but they rarely seem to engage in aggressive deadly behavior, and the causal link with homicide is a very rare event. Here we have reported the historical case of Benjamin Reynaud with a possible diagnosis of bvFTD. This historical case adds to a small number of anecdotally reported cases. On the basis of the crime dynamics, it follows that Reynaud acted in a confused, impulsive, and disorganized state and was unrepentant, feeling no remorse or emotions. We conclude that homicide is a rare extreme event in individuals with bvFTD because of their reduced planning capacity and difficulty in organizing emotion-driven behavior. Future research is required to explore these hypotheses. In addition, it remains to be established whether some offenders charged with homicides and presenting behavioral symptoms might have been diagnosed with psychiatric disorders rather than bvFTD. These would have led to an under-estimation of the percentage of homicides committed by patients with bvFTD.

Acknowledgments

The authors thank all the staff at the Departmental Archives of the Isère at Grenoble for their assistance in accessing the procedural documents relating to Benjamin Reynaud.

References

- Bang J, Spina S, Miller BL: Frontotemporal dementia. *Lancet* 386:1672–82, 2015
- Seeley WW: Behavioral variant frontotemporal dementia. *Continuum (Minneapolis)* 25:76–100, 2019
- Neary D, Snowden JS, Gustafson L, *et al*: Frontotemporal lobar degeneration: a consensus on clinical diagnostic criteria. *Neurology* 51:1546–54, 1998
- Rascovsky K, Hodges JR, Knopman D, *et al*: Sensitivity of revised diagnostic criteria for the behavioural variant of frontotemporal dementia. *Brain* 134:2456–77, 2011
- Mendez MF: Frontotemporal dementia: therapeutic interventions. *Front Neurol Neurosci* 24:168–78, 2009
- Mendez MF: The unique predisposition to criminal violations in frontotemporal dementia. *J Am Acad Psychiatry Law* 38:318–23, 2010
- Tsai RM, Boxer AL: Treatment of frontotemporal dementia. *Curr Treat Options Neurol* 16:319–33, 2014
- Diehl-Schmid J, Pernecky R, Koch J, *et al*: Guilty by suspicion? Criminal behavior in frontotemporal lobar degeneration. *Cogn Behav Neurol* 26:73–7, 2013
- Liljgren M, Naasan G, Temlett J, *et al*: Criminal behavior in frontotemporal dementia and Alzheimer disease. *JAMA Neurol* 72:295–300, 2015
- Shinagawa S, Shigenobu K, Tagai K, *et al*: Violation of laws in frontotemporal dementia: a multicenter study in Japan. *J Alzheimers Dis* 57:1221–7, 2017
- Ernst J, Krapp S, Schuster T, *et al*: Fahrtauglichkeit bei Patienten mit frontotemporaler und Alzheimer-Demenz [Car driving ability of patients with frontotemporal lobar degeneration and Alzheimer's disease]. *Nervenarzt* 81:79–85, 2010
- Fujito R, Kamimura N, Ikeda M, *et al*: Comparing the driving behaviours of individuals with frontotemporal lobar degeneration and those with Alzheimer's disease. *Psychogeriatrics* 16:27–33, 2016
- Mendez MF, Anderson E, Shapira JS: An investigation of moral judgement in frontotemporal dementia. *Cogn Behav Neurol* 18:193–7, 2005
- Mendez MF, Lauterbach EC, Sampson SM: An evidence-based review of the psychopathology of frontotemporal dementia: a report of the ANPA Committee on Research. *J Neuropsychiatry Clin Neurosci* 20:130–49, 2008
- Miller BL, Darby A, Benson DF, *et al*: Aggressive, socially disruptive and antisocial behaviour associated with frontotemporal dementia. *Br J Psychiatry* 170:150–4, 1997
- Mychack P, Kramer JH, Boone KB, *et al*: The influence of right frontotemporal dysfunction on social behavior in frontotemporal dementia. *Neurology* 56:S11–15, 2001
- Chase A: Criminality can be an early sign of frontotemporal dementia. *Nat Rev Neurol* 11:67, 2015
- Liljgren M, Landqvist WM, Rydbeck R, *et al*: Police interactions among neuropathologically confirmed dementia patients: prevalence and cause. *Alzheimer Dis Assoc Disord* 32:346–50, 2018
- Ibach B, Koch H, Koller M, *et al*: Hospital admission circumstances and prevalence of frontotemporal lobar degeneration: a multicenter psychiatric state hospital study in Germany. *Dement Geriatr Cogn Disord* 16:253–64, 2003
- Hatem Z, Amina G, Yosr H, *et al*: Homicide révélateur d'une démence [Homicide revealing dementia]. *Revue Maghrébine de Neurosciences* 4:1–4, 2009
- Bagley: Mother-son dead in murder-suicide; relative cites man's neurological disease. *Twin Cities Pioneer Press*, April 24, 2013. Available at: <https://www.twincities.com/2013/04/24/bagley-mother-son-dead-in-murder-suicide-relative-cites-mans-neurological-disease>. Accessed August 21, 2020
- Burrell JR, Halliday GM, Kril JJ, *et al*: The frontotemporal dementia-motor neuron disease continuum. *Lancet* 388:919–931, 2016
- Zago S, Poletti B, Morelli C, *et al*: Amyotrophic lateral sclerosis and frontotemporal dementia (ALS-FTD). *Arch Ital Biol* 149:39–56, 2011
- Farberov S, Pow H: Retired sheriff's deputy with ALS charged with murdering his wife and sister-in-law just days after they and his friends raised \$23,000 towards his care with the ice bucket challenge. *Daily Mail*, August 29, 2014. Available at: <https://www.dailymail.co.uk/news/article-2738262/retired-sheriff-s-deputy-als-charged-murdering-wife-sister-law-just-days-friends-raised-23-000-care-ice-bucket-challenge.html>. Accessed August 21, 2020
- Shugard J: When frontotemporal dementia leads to crime – prosecution or protection? *Alzforum*, January 13, 2015. Available at: <https://www.alzforum.org/news/research-news/when-frontotemporal-dementia-leads-crime-prosecution-or-protection>. Accessed August 21, 2020

26. Higgins D: Woman with rare dementia to be detained at specialist hospital after killing husband. *Care Appointments*, June 29, 2019. Available at: <https://careappointments.com/care-news/england/129427/woman-with-rare-dementia-to-be-detained-at-specialist-hospital-after-killing-husband>. Accessed August 21, 2020
27. Leeson L: University professor warns of more dementia awareness following tragic Sheffield killing. *Yorkshire Post*, June 28, 2019. Available at: <https://www.yorkshirepost.co.uk/news/crime/university-professor-warns-more-dementia-awareness-following-tragic-sheffield-killing-1753569>. Accessed August 21, 2020
28. Nathani M, Jaleel V, Turner A, et al: When you hear hoofbeats, think horses and zebras: the importance of a wide differential when it comes to frontotemporal lobar degeneration. *Asian J Psychiatr* 47:101875, 2020
29. Umoren IE, Fils JM, Steward JT: Frontotemporal dementia-a chameleon? *Prim Care Companion CNS Disord* 13(2):PCC.10101057, 2011
30. Dunlop J, Lemmen C: Defendant's claims of inadequate counsel in death penalty case. *J Am Acad Psychiatry Law* 43:514–16, 2015
31. Despine L-P: Naturelle Etude sul Les Facultés Intellectuelles et Morales dans leur Etat Normal et dans leurs Manifestations Anomales. [Natural Psychology: A study of the intellectual and moral faculties in their normal state and in their anomalous manifestations among madmen and criminals] *Chex le aliènes et chez les Criminels*, vol 2. Paris: F. Savy, 1868
32. von Krafft-Ebing R: *Lehrbuch der gerichtlichen Psychopathologie mit Berücksichtigung der Gesetzgebung von Oesterreich, Deutschland und Frankreich*. [Textbook of forensic psychopathology with reference to the legal codes of Austria, Germany and France]. Stuttgart: Von Ferdinand Enke, 1875
33. Pick A: *Über die Beziehungen der senilen Hirnatrophie zur Aphasie* [On the relation between aphasia and senile atrophy of the brain]. *Prag Med Wochenschr* 17:165–67, 1892
34. Rottenberg DA, Hochberg FH: *Neurological Classics in Modern Translation*. New York: Hafner Press, 1977
35. Kertesz A, Kalvach P: Arnold Pick and German neuropsychiatry in Prague. *Arch Neurol* 53:935–8, 1996
36. Mendez MF, Shapira JS: Hypersexual behavior in frontotemporal dementia: a comparison with early-onset Alzheimer's disease. *Arch Sex Behav* 42:501–9, 2013
37. Cort E, Meehan J, Reeves S, et al: Very late-onset schizophrenia-like psychosis: a clinical update. *J Psychosoc Nurs Ment Health Serv* 56:37–47, 2018
38. Howard R, Rabins PV, Seeman MV, et al: Late-onset schizophrenia and very-late-onset schizophrenia-like psychosis: an international consensus. *Am J Psychiatry* 157:172–78, 2000
39. Zarit SH, Zarit JM: *Mental Disorders in Older Adults: Fundamentals of Assessment and Treatment*. New York: Guilford Press, 2011
40. Depp CA, Jeste DV: Bipolar disorder in older adults: a critical review. *Bipolar Disord* 6:343–67, 2004
41. Yassa R, Nair NP, Iskandar H: Late-onset bipolar disorder. *Psychiatr Clin North Am* 11:117–31, 1988
42. Batts S: Brain lesions and their implications in criminal responsibility. *Behav Sci & L* 27:261–72, 2009
43. Relkin N, Plum F, Mattis S, et al: Impulsive homicide associated with an arachnoid cyst and unilateral frontotemporal cerebral dysfunction. *Semin Clin Neuropsychiatry* 1:172–83, 1996
44. Rojas-Burke J: PET scans advance as tool in insanity defense. *J Nucl Med* 34:13–26, 1993
45. Mendez MF: What frontotemporal dementia reveals about the neurobiological basis of morality. *Med Hypotheses* 67:411–8, 2006
46. Cummings JL: Frontal-subcortical circuits and human behavior. *Arch Neurol* 50:873–80, 1993
47. Panikratova YR, Vlasova RM, Akhutina TV, et al: Functional connectivity of the dorsolateral prefrontal cortex contributes to different components of executive functions. *Int J Psychophysiol* 151:70–9, 2020
48. Levi MD, Nussbaum DS, Rich JB: Neuropsychological and personality characteristics of predatory, irritable, and nonviolent offenders: support for a typology of criminal human aggression. *Crim Just & Behav* 37:633–55, 2010
49. Gilligan DG, Lennings CJ: An examination of the divergent general, specific, and other criminogenic risk/needs across neuropathic and psychopathic pathways to homicide. *Int'l J Offender Therapy & Comp Criminology* 55:693–715, 2011
50. Gilligan DG, Lennings CJ: Approach–avoidance goals and active–passive self-regulation styles in homicide offending: a pathways analysis. *Psychiatry Psychol & L* 20:590–607, 2013
51. Hanlon RE, Brook M, Stratton J, et al: Neuropsychological and intellectual differences between types of murderers: affective/impulsive versus predatory/instrumental (premeditated) homicide. *Crim Just & Behav* 40:933–48, 2013
52. Raine A, Meloy JR, Bihle S, et al: Reduced prefrontal and increased subcortical brain functioning assessed using positron emission tomography in predatory and affective murderers. *Behav Sci & L* 16:319–32, 1998
53. Lee GJ, Lu PH, Mather MJ, et al: Neuroanatomical correlates of emotional blunting in behavioral variant frontotemporal dementia and early-onset Alzheimer's disease. *J Alzheimers Dis* 41:793–800, 2014
54. Mendez MF, Carr AR, Jimenez EE, et al: Impaired empathy versus general hypoemotionality in frontotemporal dementia. *J Neuropsychiatry Clin Neurosci* 31:378–85, 2019
55. Gregory CA, Serra-Mestres J, Hodges JR: Early diagnosis of the frontal variant of frontotemporal dementia: how sensitive are standard neuroimaging and neuropsychological tests? *Neuropsychiatry Neuropsychol Behav Neurol* 12:128–35, 1999
56. Panegyres PK, Graves A, Frencham KA: The clinical differentiation of fronto-temporal dementia from psychiatric disease. *Neuropsychiatr Dis Treat* 3:637–45, 2007
57. Ducharme S, Dols A, Laforce R, et al: Recommendations to distinguish behavioural variant frontotemporal dementia from psychiatric disorders. *Brain* 143:1632–50, 2020
58. Ducharme S, Price BH, Larvie M, et al: Clinical approach to the differential diagnosis between behavioral variant frontotemporal dementia and primary psychiatric disorders. *Am J Psychiatry* 172:827–37, 2015
59. Shinagawa S, Catindig JA, Block NR, et al: When a little knowledge can be dangerous: false-positive diagnosis of behavioral variant frontotemporal dementia among community clinicians. *Dement Geriatr Cogn Disord* 41:99–108, 2016
60. Sfera A, Osorio C, Gradini R, et al: Neurodegeneration behind bars: from molecules to jurisprudence. *Front Psychiatry* 5:115–18, 2014
61. Berryessa CM: Behavioral and neural impairments of frontotemporal dementia: potential implications for criminal responsibility and sentencing. *Int'l J L & Psychiatry* 46:1–6, 2016
62. Birkhoff JM, Garberi C, Re L: The behavioral variant of frontotemporal dementia: an analysis of the literature and a case report. *Int'l J L & Psychiatry* 47:157–63, 2016
63. Lavazza A: Free will and neuroscience: from explaining freedom away to new ways of operationalizing and measuring it. *Front Hum Neurosci* 10:262–78, 2016