

# Limitations of Brain Imaging in Forensic Psychiatry

Donald Reeves, MD, Mark J. Mills, JD, MD, Stephen B. Billick, MD,  
and Jonathan D. Brodie, PhD, MD

*J Am Acad Psychiatry Law* 31:89–96, 2003

Over the several decades of its existence, brain imaging has moved from the laboratory to the bedside. Brain imaging now plays a routine role in the diagnosis of many central nervous system disorders. However, the appeal of a “snapshot” of the brain extends beyond medicine. Brain imaging, now available in color, with its simplicity and vividness, has sometimes proven irresistible to defense attorneys seeking to exonerate their clients of responsibility for their crimes. Putting aside the question of what brain imaging means for a justice system predicated on the assumption of free will, misrepresentation of brain imaging may mislead a judge and jury.

## The Technology of the Machines

Brain imaging, with its many technological variables and requirement for clinical inference, has not advanced to the point that it can be introduced in court without real and significant caveats. These same variables and inferences lend themselves to potential manipulation and distortion within the adversarial system of the court. Therefore, in using brain imaging, the forensic psychiatrist needs education in

the complexity of the technology and must make statements cautiously to avoid saying more than the science warrants.

Given the steps in brain imaging—from the generation of an image to the conclusion drawn by the expert—the psychiatrist must consider several questions. What is to be measured? Is the technique sensitive, accurate, precise, and reproducible? What do the measurements mean? Each of these questions is discussed in this article.

A brain image is the vivid representation of anatomy or physiology through a pictorial or graphic display of data. The data are some property in or of the brain (e.g., attenuation of x-rays, magnetic moments or dipoles, electrical signals, radioactive events) that the imaging technique detects, often without actually invading the brain. The image may be structural, chemical, electrical, psychological, or physiological. Techniques include computed tomography (CT), magnetic resonance imaging (MRI; including functional MRI (fMRI) techniques such as blood oxygenation level-dependent (BOLD) fMRI, and diffusion tensor imaging (DTI)), magnetic resonance spectroscopy (MRS), quantitative electroencephalography (qEEG), positron emission tomography (PET), single-photon emission computed tomography (SPECT), and magnetoencephalography (MEG).

Each imaging technique produces a detectable signal with a characteristic sensitivity, precision, accuracy, and fidelity for the physiological process being measured. To interpret these signals, the clinician must apply a model. That is, the data must be recon-

---

Dr. Reeves is Assistant Professor of Psychiatry, University of Medicine and Dentistry of New Jersey, Newark, NJ. Dr. Mills is a principal, Forensic Sciences Medical Group, Washington, DC. Dr. Billick is Clinical Professor of Psychiatry, New York Medical College, New York, NY. Dr. Brodie is the Marvin Stern Professor of Psychiatry, New York University School of Medicine, New York, NY. This paper was presented in part by Dr. Brodie at the scientific session of the 25th annual meeting of the Tri-State Chapter of the AAPL, New York, NY, January 22, 2000. Address correspondence to: Donald Reeves, MD, Department of Psychiatry, University of Medicine and Dentistry of New Jersey, 185 South Orange Avenue, Newark, NJ 07103. E-mail: reevesdo@cmhc.umdnj.edu

structed by using a set of mathematical assumptions that are framed by an experimental context or design. Such a reconstruction involves statistical analysis and comparison, from which experimental conclusions or clinical inferences may be drawn. Although the forensic psychiatrist need not possess the understanding of a physicist to use brain imaging, the psychiatrist should not ignore the technology. The generation of an image involves many assumptions, corrections, and compromises and various levels of analysis (see “Statistical Parametric Mapping” Web site).<sup>1</sup> These steps are not standardized from one technology to the next or from one machine or laboratory to the next. Thus, the image the psychiatrist reads varies, depending on the signal threshold, color, contrast, or ordinates the technician chooses or even the brand of machine available in a particular laboratory. Furthermore, the conditions under which the scan was obtained may be idiosyncratic and impossible to compare in a meaningful way with data obtained at other centers.

Not only are the steps not standardized, they are easily manipulated by a person with knowledge of the technology. Color coding, for example, can be arbitrary and may present the illusion of huge differences in some aspect of brain activity, when little actually exists. The signal-to-noise ratio (the threshold for a signal) may be changed, with the inevitable tradeoff in the type of information obtained. The analogy is that of mountaintops to valleys. If a large scale is used, the result shows only mountaintops. If the scale is decreased, then the buildings, or even the people in the valleys between the mountaintops, may become visible. The problem is that as more detail is visualized, the data become more confounded.<sup>2</sup>

### What Is Normal?

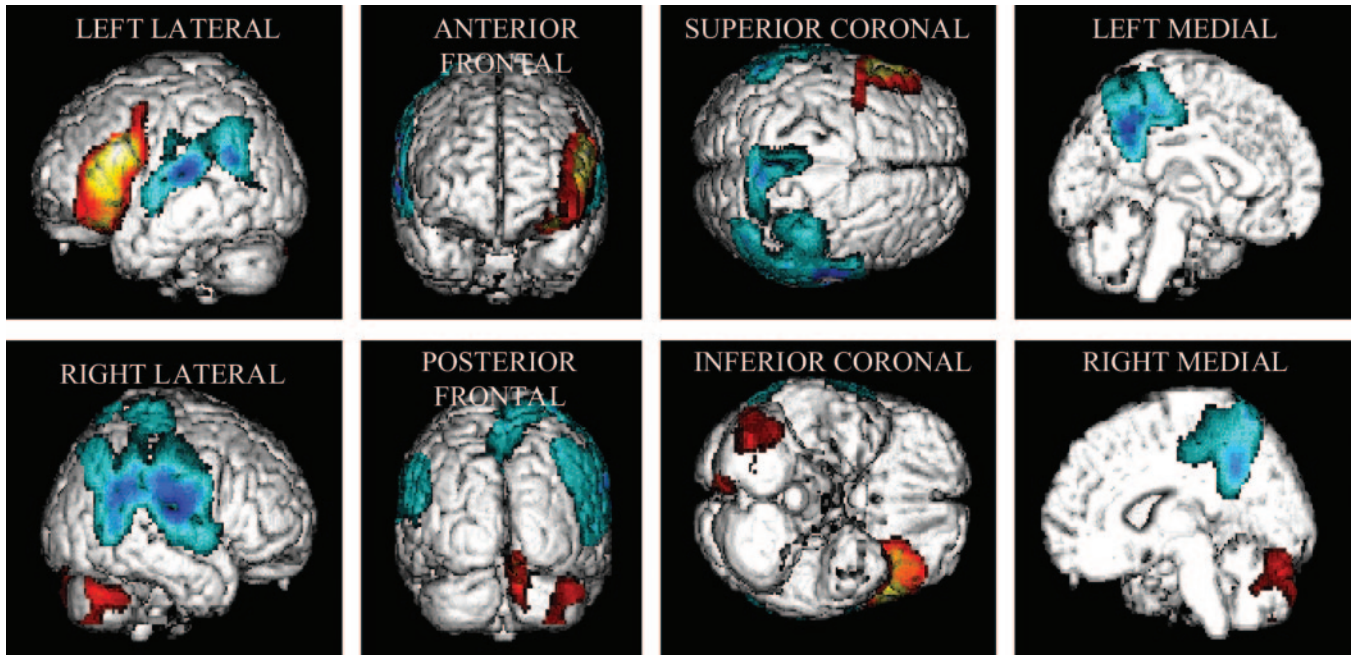
The variables do not end with the machine itself. Statistical maps of brain activity are a common and popular way to illustrate how an individual brain compares with an average brain. A statistical map is a probability function compared with a defined norm.<sup>3–7</sup> In brain imaging, the norm is obtained by pooling and averaging the brain images of normal people. The question, then, is how useful are the norms? The manner in which the norm is obtained is not always stated. Are these so-called normal people friends of the researcher, college students, employees of the hospital, or random persons from the community? How many people have provided the data that

comprise the norm? Are these people screened for use of psychoactive drugs? The norms may even be proprietary. Furthermore, to achieve a norm, a statistical manipulation must be made to compensate for differences in brain size. In other words, each head is mathematically “squeezed” to look the same size. By de-emphasizing natural variability in favor of a single average image, this procedure may give the false impression that an individual is abnormal when actually the person is merely not average.

The definition of normal may be ambiguous in brain imaging. Normal may mean the rigorous exclusion of disease or it may mean the selection of a sample that has been matched for several parameters that may (or may not) be relevant but that are not the variable under study, such as age, gender, or education. Even if a finding is abnormal, it may not be dysfunctional. A simple analogy is height. One man’s height is six feet, six inches and another’s is five feet, two inches. Both men are abnormal in that they have heights far removed from the average. However, it would be ridiculous to say that their abnormal heights necessarily make them dysfunctional. In addition, even assuming a simple Gaussian distribution of any variable (e.g., laboratory value), five percent of the normal population may have an abnormal value and yet may be defined as normal.

The definition of normal is still more slippery in forensic evaluations in which the brain activity being evaluated is purported to relate to function or behavior. In this situation, the psychiatrist should be aware of the period for which the definition of normal properly holds. Because the brain exhibits elasticity—a dynamic state of continuous adjustment to external and internal stimuli—an image taken at one time, may not resemble the image taken in the same subject at a different time. Yet both images could reflect normal function.

Furthermore, because the brain is a nearly closed system at equilibrium, considerable normal variation in components can be expected. What may be more characteristic of brain function, and thus more important for evaluation of function, are patterns of component relationships. For example, in verbal fluency tests in males, BOLD activation of fMRI is seen in the left prefrontal cortex and right cerebellum, and deactivation is seen in the posterior cingulate gyrus and in parietal and superior temporal cortices (Fig. 1).<sup>8</sup>



**Figure 1.** Verbal fluency: grouped male images. Activation is shown in the left prefrontal cortex and right cerebellum. Deactivation is shown in the posterior cingulate and the parietal and superior temporal cortices. This figure was reprinted with permission from the BMJ Publishing Group (*J Neurol Neurosurg Psychiatry* 64:492–8, 1998).

## What Brain Imaging Can Properly Accomplish

Properly conducted, brain imaging effectively presents an enormous amount of data. Imaging can localize lesions, show subject or group properties and relationships, enhance signal over noise by limiting the data to be acquired, and show functional associations. Thus, in clinical medicine, brain imaging is used in diagnosis and in assessment of treatment response. For example, a suggestive clinical examination corroborated by characteristic patchy, white-matter lesions on MRI is diagnostic of multiple sclerosis.

In research, brain imaging may be used to study pharmacology and pathophysiology. The pharmacological activity of the drug ketamine may be shown on PET through the technique of coupled-receptor imaging.<sup>9</sup> An example of this coupled-receptor strategy measures the change in binding of a radio labeled ligand to a functionally coupled receptor one or more synapses away from the original locus of drug activity (Fig. 2). In the normal state, activation of glutamatergic neurons excites neurons that contain  $\gamma$ -aminobutyric acid (GABA). The excited GABAergic neurons in turn inhibit dopamine neurons. Ketamine, however, blocks glutamate's excitatory input

to GABA neurons. The relatively quiescent GABA neurons in turn exert a diminished inhibition of dopamine-containing neurons. Thus, in the presence of ketamine, more dopamine is released at the caudate nucleus than in the normal state and can be visualized using the labeled dopamine antagonist,  $^{11}\text{C}$  raclopride. In the presence of ketamine, and the increased dopamine in the caudate nucleus,  $^{11}\text{C}$  raclopride occupies fewer caudate dopamine receptors than in the normal state.<sup>10</sup> This quantitative difference is highlighted by colors scaled to various amounts of labeled raclopride present at the caudate receptors.

However, in both clinical medicine and research, mistakes are easily made in the interpretation of the meaning of the images. For example, a clinician looking for a diagnostic marker of schizophrenia on PET finds that radiolabeled dopamine apparently binds differentially (less) to receptors in the caudate nucleus in persons who have schizophrenia compared with normal persons (Fig. 3). The finding, however, may well be spurious. The difference may only reflect that the person who has schizophrenia is taking haloperidol, which displaces the labeled dopamine. On PET, as haloperidol gradually leaves the central nervous system, radiolabeled methyl spiperone occupies

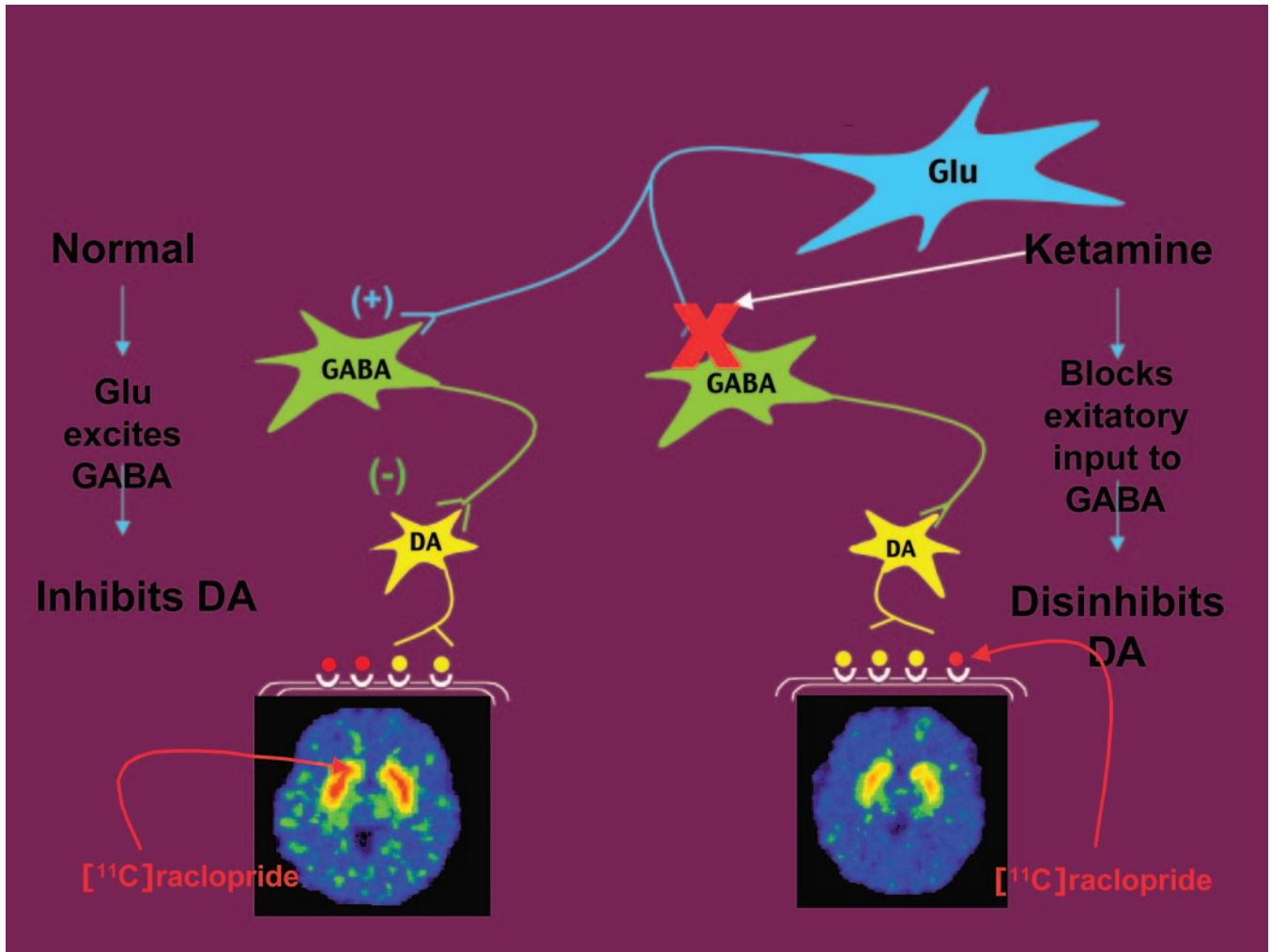


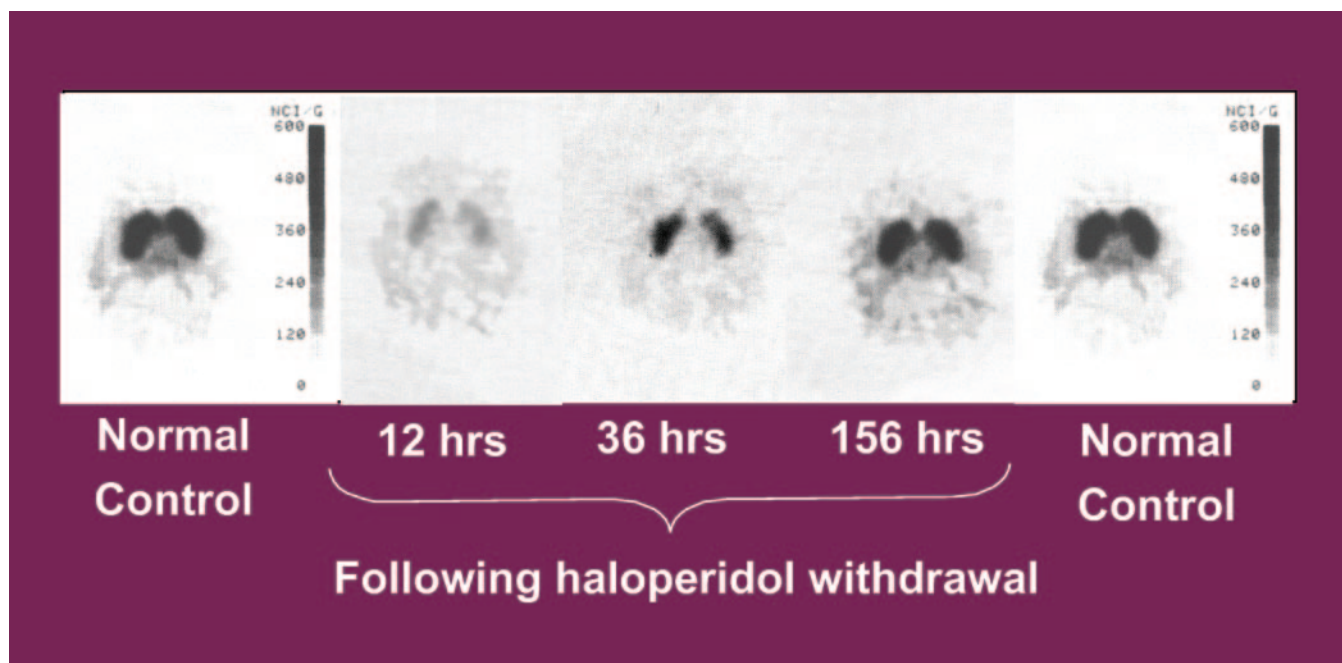
Figure 2. Propagation of drug effects.

the dopamine receptors in the caudate nucleus that haloperidol formerly occupied. After approximately six days of withdrawal, the caudate nucleus of the person with schizophrenia looks almost the same as the caudate nucleus of a normal control subject.<sup>11</sup> By contrast, it has recently been shown that release of presynaptic dopamine is characteristically higher in persons who have schizophrenia than in normal persons after an amphetamine challenge.<sup>12–15</sup>

The effect of haloperidol withdrawal highlights the larger reality, sometimes overlooked in courtroom testimony, that psychotropic drugs affect functional imaging of the brain. The psychiatrist must be aware of these effects when they are known. The effects are not always short-lived. Decreased glucose metabolism has been shown for at least one month after ingestion of cocaine.<sup>16</sup> Treatment with monoamine oxidase (MAO) inhibitors may have been dis-

continued, but the MAO itself takes months to return to pretreatment levels.<sup>17,18</sup> Chronic alcohol use affects brain function long after the abuse is eliminated.<sup>19</sup> Methamphetamine decreases dopamine transporters, and the effect lasts for weeks.<sup>20</sup>

Other confounding circumstances include inadequate control comparisons, imaging performed under dissimilar conditions, and the possibility that the subject took unacknowledged drugs. The psychiatrist should recognize that not all drug effects are known. For example, metabolic patterns before a haloperidol challenge do not distinguish persons with schizophrenia who respond to treatment from those who do not respond. However, in response to a haloperidol challenge, normal persons and medication-free treatment responders might be hypothesized to show widespread postchallenge metabolic decreases in glucose utilization. Conversely, treat-



**Figure 3.** Serial changes in receptor occupancy following neuroleptic discontinuation in a person with schizophrenia. This figure was reprinted, by permission of Elsevier Science, from "Serial  $^{18}\text{F}$ -N-methylspiroperidol PET studies to measure changes in antipsychotic drug D2 receptor occupancy in schizophrenic patients" (Smith *et al.*, *Biol Psychiatry*, 23:653–63, copyright 1988, Society of Biological Psychiatry).

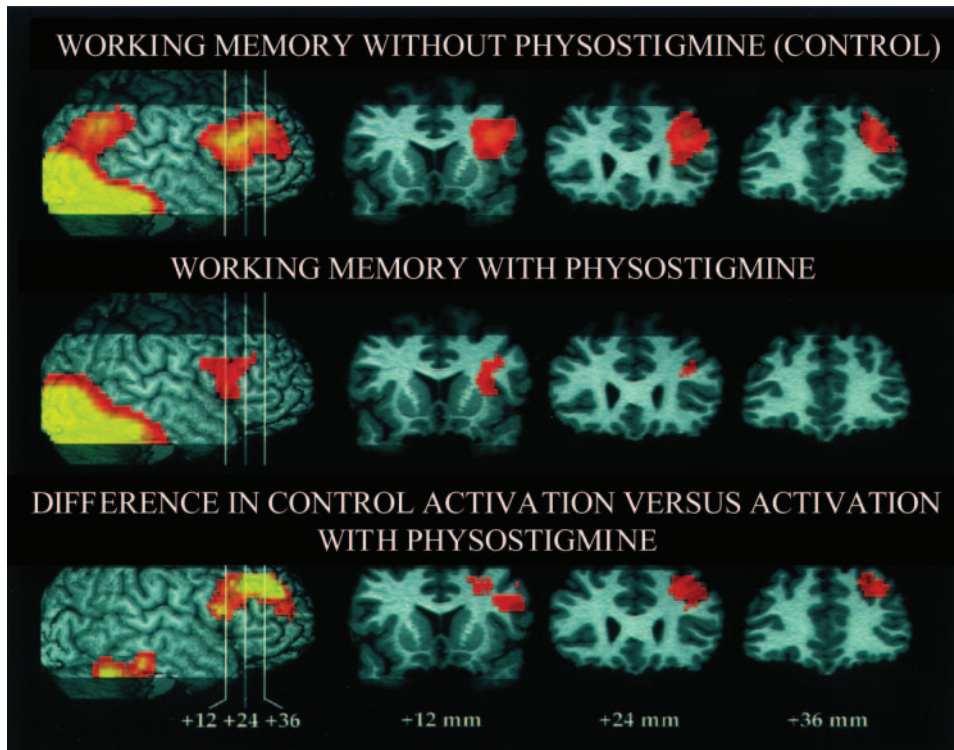
ment nonresponders might be expected to show no change in glucose metabolism after a haloperidol challenge. The results refute this hypothesis. Normal persons and treatment nonresponders show a post-challenge decrease in glucose utilization, and treatment responders show virtually no change in glucose metabolism after a haloperidol challenge.<sup>21</sup>

Unexpected results are common. It is not always the case that improved functioning on some aspect of cognition is associated with activation of the area responsible for that cognitive task. For example, cholinergic agonists such as physostigmine (an acetylcholinesterase inhibitor) improve working memory. However, enhancement of facial working memory by physostigmine is associated with reduced right prefrontal cortical activation, compared with activation in the absence of physostigmine (Fig. 4).<sup>22</sup> Figure 4 shows PET scans measuring regional cerebral blood flow. The first row shows grouped control (without physostigmine) right prefrontal cortical (rPFC) activity compared with the brain at rest when healthy subjects perform a task requiring the recall of faces the subjects have seen. The second row shows grouped rPFC activity compared with the brain at rest when the subjects are performing the memory task after having received physostigmine. Physostigmine improves the subject's performance (as mea-

sured by reaction time), but reduces the right prefrontal cortical activity in comparison with the activity present in the same region during the task in the absence of physostigmine. The difference in task-related activation between the control and physostigmine conditions is shown in the third row.

### Brain Imaging in the Courtroom

The uncertainties only increase when these images are used in the courtroom. In the neuropsychiatric evaluation for the court, brain imaging often purports to demonstrate functional status and thereby medicolegal causation. Images are used to try to demonstrate that the defendant has a psychiatric condition that caused him or her to be unaware of, or not responsible for, his or her actions or that the defendant's psychiatric condition predisposed the criminal behavior. The psychiatric conditions that imaging claims to identify include lesions that define a condition or behavior, major psychiatric disorders, and limitations of cognitive functioning. If the defendant is found criminally responsible, imaging has been used to support or define a diagnosis that suggests that a normal sentence would cause irreparable harm or be excessively punitive. However, the fact that imaging may support a psychiatric diagnosis (e.g.,



**Figure 4.** Physostigmine enhancement of facial working memory is associated with reduced right prefrontal cortical activation. This figure was reprinted, with permission, from Furey ML, Pietrini P, Haxby JV, *et al*: Cholinergic stimulation alters performance and task-specific regional cerebral blood flow during working memory. *Proc Natl Acad Sci U S A* 94:6512–16, copyright 1997, National Academy of Sciences, U.S.A.

schizophrenia) should be a separate question from whether the defendant had *mens rea* or knew the nature or wrongfulness of his or her behavior at the time of the crime.

Assume all of the above caveats have been satisfied and that an abnormality is identified by imaging. Several questions then follow. Is the abnormality related to the purported behavioral dysfunction? If the abnormality is related to the behavioral dysfunction, is it causally related or is it an epiphenomenon? Is the abnormality on imaging merely consistent with, or proof of, dysfunction? For example, when answering the first question, among other considerations, the forensic psychiatrist should give adequate attention to the temporal and spatial characteristics of the image. Typical images are acquired over long periods—minutes to hours—yet the psychiatric question may involve criminal intent that occurred over seconds.

More to the point, the assessment of criminal intent through the medium of brain imaging essentially requires the psychiatrist to identify what a thought looks like. Not only that, but the psychiatrist must identify a bad thought or an antisocial thought

and identify it, no doubt long after the criminal intent has passed. So, what does a bad thought look like? Does it leave a trail? Can the trail be imaged? Experts who claim that current imaging technology can answer such questions should be avoided. Imaging cannot identify thoughts or ascribe motives. Imaging cannot distinguish thought from deed. Although several retrospective imaging studies have associated prefrontal cortical and receptor abnormalities with violence and antisocial personality disorder,<sup>23–26</sup> it would be speculative to suggest that a particular abnormality has caused an individual to commit a particular violent act. To date, a functional deviation shown by imaging has never been causally associated with an isolated, complex behavior (including, but not limited to, assault, rape, and murder).

Conversely, most psychiatric illnesses (e.g., schizophrenia) as yet do not require brain imaging to be diagnosed. In such a case, a psychiatrist using imaging in the courtroom should state as much and also should state what information the normal image adds. If the image, by virtue of its normalcy, adds

nothing but doubt in the mind of the juror, then the ethical psychiatrist has no business plying the image in the courtroom.

Finally, and as with all other forensic criminal assessments, the defendant's desire to avoid prosecution cannot be ignored in interpreting data. Imaging data must be interpreted within a broad forensic context that seeks multiple sources of information and acknowledges that a defendant may be exaggerating or faking. Psychiatrists without forensic training may not have sufficient skepticism in assessing motivation in the forensic context.

In the courtroom, these caveats may be ignored or obfuscated by a lawyer concerned more for the client than with scientific accuracy or justice. Selective assembly of data is the lawyer's job. Misleading information may be introduced by focusing on a small but irrelevant abnormality. The lawyer may well know that the image is not proof, but may use it simply to increase confusion. Confusion may lead to reasonable doubt. Within the arena of brain imaging, the psychiatrist should not support these machinations by offering testimony that is not objective. The psychiatrist may point out concerns to the retaining attorney. If the lawyer proceeds and if the psychiatrist knows the testimony will be misconstrued, the psychiatrist may refuse to testify.

### **A Case Study: Vincent Gigante**

The Vincent Gigante case in New York<sup>27</sup> illustrates many of the problems mentioned herein. The following information is in the public record. Mr. Gigante was a reputed Mafia leader who for years had been pursued by authorities. He was charged with seven counts of murder and three counts of conspiracy to commit murder, as well as rigging business bids and extortion. Mr. Gigante had escaped prosecution with the defense that he was mentally ill and incapable of standing trial for these crimes. He was notorious for wandering the streets of Greenwich Village in his signature bathrobe. His diagnoses since 1990 included schizophrenia, multi-infarct dementia, and Alzheimer's disease.

His psychiatric history was curious. In 1967, he displayed a 40-point decrease in IQ, which, if true, suggests the occurrence of a catastrophic process such as a stroke. Yet, in the absence of a neurological deficit, in 1970, he received a diagnosis of schizophrenia and has been treated with antipsychotic medications ever since. In 1993, he had an abnormal SPECT scan

with areas of increased and decreased perfusion. In 1997, he received a diagnosis of vascular dementia, yet had a normal CT. Also in 1997, a PET scan, taken while Mr. Gigante was prescribed psychotropic medications, revealed bilateral parietal metabolic decrements, resulting in a diagnosis of Alzheimer's disease. In that same year, his mental status exam revealed inconsistent findings. For example, he could not remember the names of his children, but could recall they had "legitimate" jobs. He did not know the name of the U.S. President, but could recall the question.

In trying to understand the voluminous and complicated imaging data on Mr. Gigante that have been obtained during the past decade, it is necessary to understand and apply clinical awareness to the images that were generated. Hence, the purported 40-point decline in IQ that was noted in 1967 should have had a concomitant marker of a catastrophic brain event detectable on the CT scan taken 30 years later. If he had vascular dementia, the PET scan would not have been likely to be bilaterally symmetrical, and the CT scan should have shown evidence of the characteristic vascular lesions. The functional PET scans, used to demonstrate that his scan was abnormal in comparison with those of a group of aged-matched normal control subjects, were obtained while Mr. Gigante was being treated with chlorpromazine, nortriptyline, and several benzodiazepines for the additional diagnoses of depression, anxiety, and insomnia. By definition, drugs that are psychotropic affect the brain and hence, brain chemistry. It should not be surprising then that Mr. Gigante's PET scan would have looked abnormal when compared with those of control subjects who were medication-free. His brain images failed to support some of the diagnoses that he carried. His stable clinical picture over many years is not consistent with the presence of two dementias and schizophrenia. Finally, the dementia, depression, anxiety, or insomnia that he had otherwise been feigning for the past 30 years could have developed coincidentally.

### **Conclusion**

By its nature as a visual medium, a brain image is a compelling presentation of data. It offers a literal glimpse into the workings of the brain. The data presented, as well as the implications of the image, are also subject to distortion. In the courtroom, such imaging may serve the purpose of seduction rather

than science. The psychiatric expert who uses brain imaging in the courtroom must know the limitations of the technology and not overstate what the image reveals. This often means that the imaging expert should make claims that are far more modest and more ambiguous and less compelling than counsel would prefer. It would be a step in the right direction if the imaging expert in the courtroom were held accountable for his or her testimony by the same standards of peer review as were applied to generate the articles that attest to his or her expertise.

## References

- Wellcome Department of Cognitive Neurology: Statistical Parametric Mapping. London: University College of London; available at [www.fil.ion.ucl.ac.uk/spm](http://www.fil.ion.ucl.ac.uk/spm); accessed September 2002
- Brodie JD: Imaging for the clinical psychiatrist: facts, fantasies, and other musings [editorial]. *Am J Psychiatry* 153:145–9, 1996
- Buchel C, Holmes AP, Rees G, *et al*: Characterizing stimulus-response functions using nonlinear regressors in parametric fMRI experiments. *Neuroimage* 8:140–8, 1998
- Fletcher PC, Dolan RJ, Shallice T, *et al*: Is multivariate analysis of PET data more revealing than the univariate approach?—evidence from a study of episodic memory retrieval. *Neuroimage* 3:209–15, 1996
- Poline JB, Worsley KJ, Evans AC, *et al*: Combining spatial extent and peak intensity to test for activations in functional imaging. *Neuroimage* 5:83–96, 1997
- Signorini M, Paulesu E, Friston K, *et al*: Rapid assessment of regional cerebral metabolic abnormalities in single subjects with quantitative and nonquantitative [18F]FDG PET: a clinical validation of statistical parametric mapping. *Neuroimage* 9:63–80, 1999
- Turner R, Howseman A, Rees GE, *et al*: Functional magnetic resonance imaging of the human brain: data acquisition and analysis. *Exp Brain Res* 123:5–12, 1998
- Schloesser R, Hutchinson M, Joseffer S, *et al*: Functional magnetic resonance imaging of human brain activity in a verbal fluency task. *J Neurol Neurosurg Psychiatry* 64:492–8, 1998
- Schloesser R, Simkowitz P, Bartlett EJ, *et al*: The study of neurotransmitter interactions using positron emission tomography and functional coupling. *Clin Neuropharmacol* 19:371–89, 1996
- Smith GS, Schloesser RL, Brodie JD, *et al*: Glutamate modulation of dopamine measured *in vivo* with positron emission tomography (PET) and <sup>11</sup>C raclopride in normal human subjects. *Neuropsychopharmacology* 18:18–25, 1998
- Smith M, Wolf AP, Brodie JD, *et al*: Serial <sup>18</sup>F-*N*-methylspiroperidol PET studies to measure changes in antipsychotic drug D2 receptor occupancy in schizophrenic patients. *Biol Psychiatry* 23:653–63, 1988
- Abi-Dargham A, Gil R, Krystal J, *et al*: Increased striatal dopamine transmission in schizophrenia: confirmation in a second cohort. *Am J Psychiatry* 155:761–7, 1998
- Breier A, Su TP, Saunders R, *et al*: Schizophrenia is associated with elevated amphetamine-induced synaptic dopamine concentrations: evidence from a novel positron emission tomography method. *Proc Natl Acad Sci U S A* 94:2569–74, 1997
- Laruelle M, Abi-Dargham A, van Dyck CH, *et al*: Single photon emission computerized tomography imaging of amphetamine-induced dopamine release in drug-free schizophrenic subjects. *Proc Natl Acad Sci U S A* 93:9235–40, 1996
- Laruelle M, Abi-Dargham A, Gil R, *et al*: Increased dopamine transmission in schizophrenia: relationship to illness phases. *Biol Psychiatry* 46:56–72, 1999
- Volkow ND, Fowler JS, Wolf AP, *et al*: Changes in brain glucose metabolism in cocaine dependence and withdrawal. *Am J Psychiatry* 148:621–6, 1991
- Arnett CD, Fowler JS, MacGregor RR, *et al*: Turnover of brain monoamine oxidase measured *in vivo* by positron emission tomography using L-[<sup>11</sup>C]deprenyl. *J Neurochem* 49:522–7, 1987
- Fowler JS, Volkow ND, Logan J, *et al*: Slow recovery of human brain MAO B after L-deprenyl (Selegiline) withdrawal. *Synapse* 18:86–93, 1994
- Volkow ND, Mullani N, Gould L, *et al*: Effects of acute alcohol intoxication on cerebral blood flow measured with PET. *Psychiatry Res* 24:201–9, 1988
- McCann UD, Wong DF, Yokoi F, *et al*: Reduced striatal dopamine transporter density in abstinent methamphetamine and methcathinone users: evidence from positron emission tomography studies with [<sup>11</sup>C]WIN-35, 428. *J Neurosci* 18:8417–22, 1998
- Bartlett EJ, Brodie JD, Simkowitz P, *et al*: The effect of a haloperidol challenge on regional brain metabolism in neuroleptic-responsive and non-responsive schizophrenics. *Am J Psychiatry* 155:337–43, 1998
- Furey ML, Pietrini P, Haxby JV, *et al*: Cholinergic stimulation alters performance and task-specific regional cerebral blood flow during working memory. *Proc Natl Acad Sci U S A* 94:6512–16, 1997
- Amen DG, Stubblefield M, Carmichael B, *et al*: Brain SPECT findings and aggressiveness. *Ann Clin Psychiatry* 8:129–37, 1996
- Raine A, Meloy JR, Bihrlle S, *et al*: Reduced prefrontal and increased subcortical brain functioning assessed using positron emission tomography in predatory and affective murderers. *Behav Sci Law* 16:319–32, 1998
- Raine A, Lencz T, Bihrlle S, *et al*: Reduced prefrontal gray matter volume and reduced autonomic activity in antisocial personality disorder. *Arch Gen Psychiatry* 57:119–27, 2000
- Tiihonen J, Kuikka JT, Bergstrom KA, *et al*: Single photon emission tomography imaging of monoamine transporters in impulsive violent behavior. *Eur J Nucl Med* 24:1253–60, 1997
- U.S. v. Gigante, 982 F.Supp. 140, 159 (E.D.N.Y. 1997)